

Medical, ethical, and legal aspects of hematopoietic stem cell transplantation for Crohn's disease in Brazil

Milton Artur Ruiz, Roberto Luiz Kaiser Junior, Lilian Piron-Ruiz, Priscila Samara Saran, Lilian Castiglioni, Luiz Gustavo de Quadros, Tainara Souza Pinho, Richard K Burt

ORCID number: Milton Artur Ruiz 0000-0003-2212-4883; Roberto Luiz Kaiser Junior 0000-0003-1952-1255; Lilian Piron-Ruiz 0000-0002-3602-5897; Priscila Samara Saran 0000-0002-5594-6106; Lilian Castiglioni 0000-0002-9999-2673; Luiz Gustavo de Quadros 0000-0001-9586-8109; Tainara Souza Pinho 0000-0003-3531-079X; Richard K Burt 0000-0002-0922-4145.

Author contributions: Ruiz MA, Kaiser Junior RL and Burt RK conceived the study, drafted and reviewed the manuscript; Piron-Ruiz L, Saran PS, and De Quadros LG contributed to the literature review, discussed the subject and reviewed the final manuscript text; Castiglioni L and Pinho TS provided statistical support; All authors approved the final version of the article.

Conflict-of-interest statement:

Authors declare no conflict of interests for this article.

Open-Access: This article is an open-access article that was selected by an in-house editor and fully peer-reviewed by external reviewers. It is distributed in accordance with the Creative Commons Attribution NonCommercial (CC BY-NC 4.0) license, which permits others to distribute, remix, adapt, build

Milton Artur Ruiz, Department of Bone Marrow Transplant, Beneficência Portuguesa Hospital, São José do Rio Preto 15090 470, Brazil

Roberto Luiz Kaiser Junior, Department of Proctology, Beneficencia Portuguesa Hospital, São José do Rio Preto 15090 470, Brazil

Lilian Piron-Ruiz, Priscila Samara Saran, Tainara Souza Pinho, Department of Bone Marrow Transplantation, Beneficência Portuguesa Hospital, São José do Rio Preto 15090 470, Brazil

Lilian Castiglioni, Genetics and Molecular Biology, FAMERP- Faculdade de Medicina de São José do Rio Preto, São José do Rio Preto 15090 470 Brazil

Luiz Gustavo de Quadros, Department of Endoscopy, Beneficência Portuguesa Hospital, ABC Medical School, São Bernardo 15015 110, Brazil

Richard K Burt, Department of Medicine, Northwestern University Feinberg School of Medicine, Chicago, IL 60611, United States

Corresponding author: Milton Artur Ruiz, MD, PhD, Emeritus Professor, Department of Bone Marrow Transplant, Beneficência Portuguesa Hospital, Rua Catarina Nucci Parise 760, São José do Rio Preto 15090 470, Brazil. milruiz@yahoo.com.br

Abstract

Crohn's disease (CD) is a chronic inflammatory bowel disease that can affect any part of the gastrointestinal tract. The etiology of CD is unknown; however, genetic, epigenetic, environmental, and lifestyle factors could play an essential role in the onset and establishment of the disease. CD results from immune dysregulation due to loss of the healthy symbiotic relationship between host and intestinal flora and or its antigens. It affects both sexes equally with a male to female ratio of 1.0, and its onset can occur at any age, but the diagnosis is most commonly observed in the range of 20 to 40 years of age. CD diminishes quality of life, interferes with social activities, traumatizes due to the stigma of incontinence, fistulae, strictures, and colostomies, and in severe cases, affects survival when compared to the general population. Symptoms fluctuate between periods of remission and activity in which complications such as fistulas, strictures, and the need for bowel resection, surgery, and colostomy implantation make up the most severe aspects of the disease. CD can be progressive and the complications recurrent despite treatment with anti-inflammatory drugs, corticosteroids,

upon this work non-commercially, and license their derivative works on different terms, provided the original work is properly cited and the use is non-commercial. See: <http://creativecommons.org/licenses/by-nc/4.0/>

Manuscript source: Invited manuscript

Received: May 2, 2020

Peer-review started: May 2, 2020

First decision: May 24, 2020

Revised: July 8, 2020

Accepted: August 25, 2020

Article in press: August 25, 2020

Published online: October 26, 2020

P-Reviewer: Chiba T, Sipos F

S-Editor: Zhang L

L-Editor: Webster JR

P-Editor: Li JH



immunosuppressants, and biological agents. However, over time many patients become refractory without treatment alternatives, and in this scenario, hematopoietic stem cell transplantation (HSCT) has emerged as a potential treatment option. The rationale for the use of HSCT for CD is anchored in animal studies and human clinical trials where HSCT could reset a patient's immune system by eliminating disease-causing effector cells and upon immune recovery increase regulatory and suppressive immune cells. Autologous HSCT using a non-myeloablative regimen of cyclophosphamide and anti-thymocyte globulin without CD34+ selection has been to date the most common transplant conditioning regimen adopted. In this review we will address the current situation regarding CD treatment with HSCT and emphasize the medical, ethical, and legal aspects that permeate the procedure in Brazil.

Key Words: Crohn disease; Hematopoietic stem cell transplant; Stem cell therapy; Autologous transplant; Ethics; Treatment

©The Author(s) 2020. Published by Baishideng Publishing Group Inc. All rights reserved.

Core Tip: Hematopoietic stem cell transplantation (HSCT) is an alternative treatment for patients with Crohn's disease, which is severe and refractory to conventional treatments. Prolonged remissions are described with the autologous as in the allogeneic modality. In this review, we describe the rationale, justifications, and results of HSCT in studies from various locations. Unpublished data and results from a relevant series are described. The ethical and legal medical aspects that permeate compassionate treatment in Brazil are defined and presented.

Citation: Ruiz MA, Junior RLK, Piron-Ruiz L, Saran PS, Castiglioni L, Quadros LG, Pinho TS, Burt RK. Medical, ethical, and legal aspects of hematopoietic stem cell transplantation for Crohn's disease in Brazil. *World J Stem Cells* 2020; 12(10): 1113-1123

URL: <https://www.wjgnet.com/1948-0210/full/v12/i10/1113.htm>

DOI: <https://dx.doi.org/10.4252/wjsc.v12.i10.1113>

INTRODUCTION

Crohn's disease (CD) is a severe chronic relapse-remitting heterogeneous inflammatory bowel disease that can affect any part of a patient's digestive tract^[1,2]. A progressive disease, CD tends to become more severe over the years with the appearance of complications such as strictures, abscesses, and perforations, and as a result of undergoing surgery, the aftereffect of which may be short gut syndrome.

The onset of symptoms may occur in children, but CD is diagnosed most commonly between the second and third decades of life. There is no sexual preference in the distribution of cases, with developed countries having the highest number of cases and a clear trend of growth and diagnosis of CD throughout the world. The prevalence of the disease is highest in Europe, followed by Canada, the United States, Australia, and New Zealand. The incidence of CD is increasing in regions such as Asia and South America that traditionally have had a low prevalence^[3,4].

Risk factors include genetic, epigenetic, and environmental susceptibility^[2,4-7]. Over 200 alleles are linked to inflammatory bowel disease, 37 of which are specific to CD, including multiple gene mutations of multiple nucleotide-binding oligomerization domain-containing protein 2 (NOD2). Despite genomic advances, this knowledge is not yet part of clinical practice and treatment algorithms^[2,6]. The risk of CD may also increase due to lifestyle, such as smoking or the use of multiple antibiotics in childhood that could alter gut flora^[8].

CLINICAL, DIAGNOSIS AND TREATMENT FEATURES

The clinical presentation and diagnosis of CD depend upon disease location and

severity. The spectrum of symptoms includes crises of abdominal pain most often located in the lower right quadrant, diarrhea sometimes uncontrolled and numerous, hematochezia and or melena, fever, weight loss, fatigue, and anorexia. Perianal disease can be present in a significant number of patients and sometimes be the first sign or symptom. Extraintestinal manifestations such as joint, skin, or eye involvement, among others, may be present as other autoimmune diseases are associated with CD^[1,2].

Diagnosis is based on characteristic clinical, radiological, endo-colonoscopy, and histologic presentation. However, simple pattern recognition is a habit that can cause a missed diagnosis of other necessary treatable conditions. Mimics of CD arise from medications such as NSAIDs, mycophenolate mofetil, high dose estrogens, infections such as cytomegalovirus, herpes virus, *Clostridium difficile*, other autoimmune diseases such as Behcet's syndrome or celiac disease, and a genetic immunoglobulin deficiency especially in early-onset CD of childhood^[2]. The typical endoscopic pattern of CD is segmental or skipped involvement with a cobble stone pattern produced by serpiginous aphthous ulcerations interspersed with nodular mucosa edema. The classic histologic pattern of CD is an epithelioid granuloma. Chronic inflammatory lymphoid transmural infiltrate, and goblet cell preservation and pyloric gland metaplasia are common histological findings^[9].

The treatment is complex and depends on the patient's assessment criteria and severity of the patient's condition^[10]. The criteria used for this decision are, among others, the age at diagnosis of the disease, location and behavior, and type of lesion observed, data that make up the Montreal Classification^[11]. Additionally, the presence of perianal disease, smoking, positive antimicrobial biomarkers, and NOD2 mutation reflect possible severity and disease progression. Anti-inflammatory, corticosteroids, antibiotics, immunosuppressants, and biologic agents, alone or combined, and surgery are the treatment basis of the disease^[9]. Several treatment algorithms exist, from bottom-up from gradual progression to the use of biological agents as the last of the scale to the opposite approach, top-down with the utilization of biological agents first. Concerning biological agents, anti-TNF alpha (infliximab, adalimumab, and certolizumab pegol), the first described and most used as a rule to start treatment and in the absence of primary or secondary response may be substituted by other biologicals such as anti-alpha four integrin (vedolizumab) and anti-leucine 12/23 (ustekinumab)^[10]. However, the sequence described for the use of biologicals is controversial^[10]. Current treatment results are not entirely satisfactory because prescription drug treatment is chronic, some patients become refractory, and recurrent surgical procedures compel patients to seek alternative treatments, including autologous hematopoietic stem cell transplantation (HSCT).

RATIONAL FOR HSCT

The rationale of HSCT transplantation for autoimmune diseases began in 1985 with a report of marrow reconstitution after allogeneic bone marrow transplantation (BMT) in mice with autoimmune diseases previously lethally irradiated^[12]. In 1989, total body irradiation followed by syngeneic allogeneic BMT was used to treat adjuvant-induced arthritis in rats^[13]. The same was observed even with autologous BMT two years later^[14].

These findings resulted in the concept of immunopathology that underlies lymphoablation, eradication of the cells involved, and reconstitution of the immune system with BMT to treat various autoimmune diseases^[15-17].

Animal models have been developed as paradigms of CD^[18]. These models permit studies of T helper cell type 1 immune responses, the role of cytokines such as interleukins (*e.g.*, IL12 or IL23), epithelial and barrier alterations, leukocyte trafficking to the inflamed mucosa, the role of the adhesion molecules, innate immunity, NOD2, and gut microbiome in the pathogenesis of CD. A Brazilian experimental animal inflammatory bowel disease study demonstrated that high dose cyclophosphamide followed by HSCT modulated mucosal immunity and accelerated immune reconstitution^[19].

In humans, immune analysis of Treg cells (CD4+CD25brightcells) in the peripheral blood of 13 patients with CD before HSCT demonstrated that the mean percentage of CD4+CD25brightcells ($2.62\% \pm 2.01\%$, $n = 13$) was reduced ($P < 0.01$) compared with normal volunteers ($3.86\% \pm 1.67\%$, $n = 8$). Post-HSCT, compared with pre-HSCT, a robust increase in the percentage of CD4+CD25brightcells was observed: Pre-HSCT ($2.6\% \pm 2.01\%$, $n = 13$); 6 months post-HSCT $2.91\% \pm 1.74\%$ ($P < 0.05$, $n = 9$); 1 year

post-HSCT ($3.55\% \pm 1.63\%$, $n = 13$, $P < 0.05$); 2 years post-HSCT ($3.36\% \pm 1.63\%$, $n = 10$, $P < 0.05$); 3 years post-HSCT ($3.99\% \pm 0.78\%$, $n = 4$, $P =$ not significant)^[20]. In another human study, when HSCT was compared to anti-tumor necrosis factor (TNF) treatment, the peripheral blood post-HSCT, unlike anti-TNF therapy, demonstrated expansion of naïve B cells and a decrease in memory T cells^[21]. HSCT, but not anti-TNF therapy, induced a significant decrease in intestinal luminal T cell content^[21].

CD AND HSCT

The worldwide experience with HSCT for CD, perspectives for new studies, and ethical and legal aspects unique to the Brazilian situation are summarized in this section. The concept of HSCT for CD began with case reports of coincidental CD remission after allogeneic or autologous HSCT performed for a standard hematologic or neoplastic indication^[22-27]. The first report of autologous HSCT performed for CD appeared in 2003^[20-28]. Since then, a series of phase II studies for CD have been performed in several different countries^[29-32].

In 2010, the first long-term follow-up study reported 25 patients^[20]. The study aimed to evaluate HSCT safety and clinical evolution with a non-myeloablative conditioning regimen in patients with severe CD refractory to conventional treatments. The mobilization regimen consisted of cyclophosphamide 2 g/m^2 in a single dose and G-CSF 10 µg/kg/d after the fifth day until the day of hematopoietic stem cells collection. The peripheral blood stem cells (PBSCs) were CD34+ selected *ex vivo*. The conditioning regimen consisted of 200 mg/kg cyclophosphamide and 6 mg/kg rabbit anti-thymocyte globulin or 90 mg/kg horse anti-thymocyte globulin. All patients achieved clinical remission with normalization of clinical parameters, Crohn's Disease Activity Index (CDAI) < 150 , and Craig Crohn Severity Index < 16 . HSCT-related mortality in these patients was zero.

Eighteen patients completed five years of follow-up with relapse-free treatment-free survival of 91% in the first year, 63% in the second, 57% in the third, 39% in the fourth, and 19% in the fifth year after HSCT^[20]. No prescription drug therapy trial has ever looked at a drug-free endpoint as drug trials are based on chronic treatment using the study drug, and other drugs such as corticosteroids may also be used during the study. The endpoint of drug trials is clinical remission defined as a CDAI of less than 150 while on treatment. Drugs achieve clinical remission of 40 to 50% at one year that declines with time. In the HSCT trial, when the outcome was defined as in drug trials, the clinical remission (CDAI < 150) was over 80% every year for five years^[20]. This study was a milestone for the treatment of CD, and subsequently, the European group of Autoimmune Diseases of European Society for Blood and Marrow Transplantation organized a randomized clinical trial, termed autologous stem cell transplantation in Crohn (ASTIC) to compare the effect of HSCT with standard treatment of the disease^[33].

In the ASTIC trial, eleven transplant centers from 6 countries with 45 patients participated in the study. The first patient was randomized in 2007 and the last in 2011, in a study aimed at evaluating patients who were severe and refractory to multiple drug treatments. Two groups, the first being the group for immediate transplantation and the second for treatment with 4.0 g/m^2 cyclophosphamide and stem cell collection but delayed HSCT until after one year. Therefore, both the transplant and control group received treatment with 4.0 g/m^2 cyclophosphamide and stem cell mobilization. Unlike the earlier study, the stem cells, *i.e.*, the PBSCs, were not selected or purged of lymphocytes.

The primary outcome of the ASTIC trial was to assess the presence of sustained disease remission (SDR) in patients in both groups. SDR consisted of clinical remission that is CDAI < 150 , absence of immunosuppressive or biological corticosteroids for at least three months before one year of evaluation and absence of endoscopic or radiological evidence of active disease (erosion) in any part of the digestive system. The secondary objectives were the individual points of the primary objective. Twenty-three patients were allocated to the transplant group and 22 to the standard treatment group.

After the elapsed time, only two patients in the transplant group (8.7%) had SDR and one (4.5%) in the standard treatment group. While the primary endpoint was not significant, the secondary objectives were all statistically significant in favor of HSCT. These secondary endpoints included no active treatment, CDAI below 150, and no endoscopic or radiological evidence of active (erosive) disease.

Seventy-six serious adverse events occurred in the transplant group and 38 in the

control group and one death in the former group due to veno-occlusive liver disease. These results led to the conclusion that HSCT did not improve SDR after one year of observation, and the procedure carried high toxicity, and therefore, there was no indication for the use of HSCT in patients with CD outside of a clinical trial^[33].

A divergent opinion on this article was published in a letter to the editor^[34], in which several points were addressed: First was the definition of remission that had never been vetted or used in any prior drug trial, the second was the dose of 4 g/m² of cyclophosphamide in the control arm that was itself an experimental treatment, and third that the definitive randomized trial should only be initiated in centers that have significant HSCT experience in CD^[34]. To address the definition used for disease remission, the ASTIC group published an assessment of patients undergoing HSCT using traditional criteria for remission^[35]. In addition to the 23 patients in the immediate transplant group, another 17 patients were added who had the procedure delayed for one year, making 40 patients. As one death had already occurred, and there was a withdrawal, the final evaluation occurred in 38 patients.

Clinical remission and improvement of clinical parameters and complete healing of the mucosa occurred in 50% of patients who underwent HSCT. Also, the patient-reported outcomes and the patients' quality of life significantly improved. The study concluded that HSCT, when evaluated according to the traditional prescription drug study criteria, resulted in significant endoscopic mucosal healing and quality of life benefits for the patients^[35]. Another publication from an experienced center that participated in the ASTIC trial with 35 patients, 13 of which were from the original ASTIC study, reported no mortality and concluded that autologous HSCT is effective in refractory CD and that the procedure, although not a cure as currently designed, changes the course of 80% of patients^[36].

CD AND HSCT IN BRAZIL

HSCT for CD in Brazil follows the guidelines and rules described in the Brazilian Medical Ethics Code. Brazilian health care/insurance plans contested the costs of the research project and treatment, but a Federal Medical Council position validated the research project and opened the legal path for patients, refractory, and without other treatment, to participate in HSCT. At present, patients wishing to undergo HSCT must follow all the legal steps described and follow the inclusion criteria to participate in the only autologous HSCT protocol underway in Brazil.

Communications took place in meetings, congresses, scientific events, and case reports of patients from the study projects^[37-40]. The Brazilian Medical Society, with involvement and authority over HSCT, including CD, is the Brazilian Society of Bone Marrow Transplantation (SBTMO). Every three years, a clinical guidelines meeting occurs, and one of the subjects is autoimmune diseases. In addition to the annual SBTMO meeting, reports and position papers are prepared and published from these events^[41]. Among the most cited autoimmune diseases recommended for HSCT are multiple sclerosis, systemic sclerosis, and CD. Recently SBTMO wrote a position paper accepted for publication. The suggestion is to introduce HSCT into clinical practice for those diseases that are considered experimental in the country^[42].

Four Brazilian institutions performed autologous HSCT treatment for CD patients. Our institution in São Jose Rio Preto is the only Brazilian institution to develop research projects with HSCT in CD. The first project closed after completing the enrollment of 40 patients. The final data from this trial are still in analysis and yet to be published. However, a summary of the first 14 cases highlighted the low toxicity of autologous HSCT, with few adverse events, no deaths, and immediate improvement in patients' quality of life^[43]. The second is in progress, recruiting patients since January 2019 to include more than ten patients in this report. The Hospital Israelita Albert Einstein, Hospital de Clinicas, Faculty of Medicine, USP of Ribeirão Preto, and Hospital São Camilo of São Paulo performed six, two, and one HSCT procedure, respectively, for CD patients (Table 1).

Our studies at São Jose do Rio Preto mimicked Chicago's protocol with slight differences and had safety objective and procedure validation in Brazil^[20].

Inclusion criteria were CDAI greater than 150, intestinal lesions detected by colonoscopy or capsule endoscopy, disease refractory to treatment, a history of adverse reactions to two biologic agents, conditions preventing additional surgical procedures and risk of a permanent stoma and rectal amputation. All patients with significant comorbidities were excluded, as were patients in remission and those with coexisting psychiatric disorders, infectious diseases, intraabdominal abscesses, fistulae,

Table 1 Autologous hematopoietic stem cell transplantation for Crohn's disease in Brazil-2013/2019

Centres	pts	%
Hospital Beneficencia Portuguesa SJ Rio Preto, São Paulo	50	86.2%
Hospital Israelita Albert Einstein, São Paulo	6	10.3%
Hospital das Clínicas FMUSP Ribeirão Preto, São Paulo	2	3.4%
São Camilo Hospital São Paulo, São Paulo	1	1.7%
Total	59	100%

HSCT – Hematopoietic stem cell Transplantation; CD – Crohn disease.

ulcerative colitis, or neoplastic disorders.

The difference was a reinfusion of PBSCs without selection or manipulation. In the second CD HSCT trial that is currently ongoing at São Jose do Rio Preto, the inclusion criteria are the same, and after HSCT, a maintenance dose of tacrolimus is taken orally for one year.

The demographics such as Montreal classification, extraintestinal manifestations, and previous therapy in 50 patients who have undergone HSCT at São Jose do Rio Preto are shown in [Table 2](#). The relapse-free survival of these patients for up to five years after HSCT is shown in [Figure 1](#). After one year of follow-up, 90.57% of the patients were clinically asymptomatic and remained free of immunosuppressive drugs, biological agents, or surgery related to CD. The results of relapse-free survival after two, three, four, and five years of HSCT were 82.1%, 69.45%, 53.42%, and 21.37%, respectively.

Finally, of note, Brazil's first report of HSCT in CD occurred in 2013 at Beneficencia Portuguesa Hospital of São José do Rio Preto, São Paulo^[37] in a female patient with severe CD, refractory to anti-inflammatory agents, corticosteroids, immunosuppressants, and two biological anti-TNF α drugs, infliximab, and adalimumab. She had repeated episodes of abdominal pain, more than 20 bowel movements/day, hematochezia, weight loss, depression, psychosis, arthralgia, psoriatic-like skin lesions, and a prior 40 cm bowel resection due to stenosis. Before HSCT, colonoscopy showed severe ileitis in the ileum cecal valve, right and left colon, and rectum. The patient has remained in a drug-free clinical and endoscopic remission, more than five years after HSCT^[37].

DISCUSSION

HSCT is an established procedure indicated for the treatment of hematological diseases, solid tumors, and immune disorders^[44]. The indications for HSCT for malignancies have increased mainly due to plasma cell and lymphoproliferative disorders extending to older patients^[45]. Autoimmune diseases affect approximately 3% of the world population and the indications and number of patients treated for autoimmune disease, particularly for relapsing-remitting multiple sclerosis, systemic sclerosis, and CD, have also been increasing since the first case reports in 1995^[46,47]. CD is currently the third most common autoimmune disease treated with HSCT, according to the European Society for Blood and Marrow Transplantation Registry^[48].

Given the published data, from the ecclesiastical, secular, societal, or individual patient point of view, is it ethical to refuse HSCT in a patient with severe CD refractory to the usual medical treatments? This question is answered in the Brazilian Medical Code of Ethics. Chapter 1, in the fundamental principles in article V, where it states that it is up to the doctor to continuously improve his knowledge and use the best of scientific progress for the benefit of the patient and the Society^[49]. Article 102 is explicit in that it is forbidden for the doctor to stop using correct therapy and release it in the country. In the single article paragraph, there is an indication of the performance of experimental treatment with the consent of the patient or his legal representative, after adequate clarification of the situation and the possible redundant consequences of the proposed treatment^[50].

The Federal Council of Medicine considers HSCT for CD to be an experimental treatment advising that it should carry out in the country as part of a research project and in an institution that has a transplant program accredited with the SNT, and duly

Table 2 Demographic and clinical characteristics of Crohn's disease patients who underwent hematopoietic stem cell transplantation in Beneficencia Portuguesa Hospital SJ Rio Preto (A), São Paulo - Brazil - 2013/2019

Patients, <i>n</i>	50	%
Age, HSCT	32.6 (15-50)	
Sex/gender - male/female	22/28	46/54
Time elapsed-symptoms/diagnosis (yr)	6.5 (0-23)	
Time elapsed-diagnosis/HSCT (yr)	9.26 (1-28)	
Montreal classification		
Age diagnosis		
A1	14	28.0
A2	35	70.0
A3	1	2.0
Localization	1	2.0
L1	3	6.0
L2	37	74.0
L3	9	18.0
L3 + L4	9	18.0
Behavior	30	60.0
B1	11	22.0
B2		
B3		
Perianal disease	22	44.0
Extraintestinal diseases	42	84.0
Articular	41	97.6
Skin	8	19.0
Eye	4	9.5
Other	6	14.3
Autoimmune concomitant or previous disease	8	16.0
Fistulas	17	34.0
Anal	12	70.6
Anorectal	4	23.8
Anovaginal	3	17.3
Enteroenteral	4	23.5
Enterovaginal	1	5.9
Enterocutaneous	1	5.9
Other	1	5.9
Ostomia at HSCT	8	16.0
Familial History	10	20.0
Previous surgeries	33	66.0
Previous therapy		
Sulfasalazine	39	78.0
Mesalazine	47	94.0
Corticosteroids	50	100

Budesonide	10	20.0
Azathioprine	44	88.0
6-Mercaptopurine	1	2.0
Methotrexate	17	34.0
Cyclosporine	4	8.0
Infliximab	49	98.0
Adalimumab	47	94.0
Certolizumab pegol	4	8.0
Vedolizumab	9	18.0
Ustekinumab	7	14.0
Natalizumab	1	2.0
Etanercept	1	2.0
CDAI	297.8 (155-576.2)	
HBI	17.54 (4-48)	
CSI	23.16 (10-36)	
CDEIS	11.29 (0-36)	
SES-CD	14.08 (0-43)	

CDAI: Crohn’s Disease Activity Index; HBI: Harvey Bradshaw index.

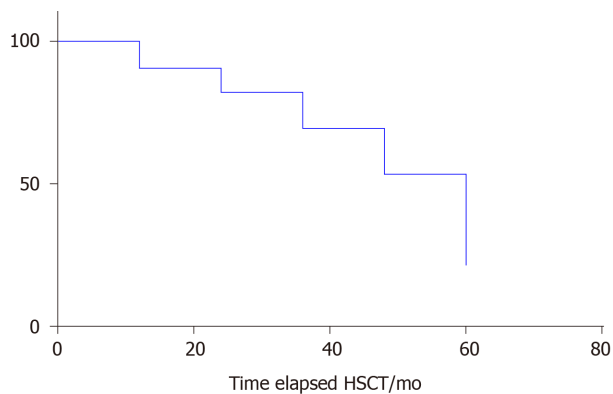


Figure 1 Clinical relapse-free survival of 50 patients (2013–October 2019).

approved by the National Council of Ethics and Research^[49-51]. As a result, patients who have health plans, and do not obtain a resolution with conventional treatment, have the right to have paid for even experimental treatments as long as they follow the ethical, legal precepts and insert in research protocols. In this scenario, patients with autoimmune diseases and CD who are not showing results with conventional treatments, with no therapeutic option and or risk of worsening their disease, may opt for experimental treatments through the courts^[50,51].

The future of HSCT for CD is to continue to tweak the regimen to make it safer and to achieve even longer and more long-lasting results without evidence of disease, that is, durable clinical remission on no drug therapy, and imaging, endoscopic, and histologic remission. Based on the literature and data cited, we consider that there is a place for autologous HSCT in the treatment of patients with severe and refractory CD where the death rate is zero and toxicity is low and that position was highlighted in a recent SBTMO position and a correspondence paper^[42-52]. It is well known that autologous HSCT provided treatment-free remission in a large number of patients, but the majority persisted with histological evidence of disease. A pilot study of non-myeloablative allogeneic HSCT reported the data of nine CD patients after five years of follow-up^[53]. In three patients, unselected matched sibling PBSCs were used and

umbilical cord blood was used in six patients. The inclusion criteria for allogeneic HSCT were related to the severity and refractoriness to conventional treatments similar to those described in other studies. The non-myeloablative conditioning regimen used was cyclophosphamide, alemtuzumab, and fludarabine. Calcineurin inhibitor for six to nine months was used to prevent graft *vs* host disease (GVHD). No patient died during transplantation. No patient had acute GVHD, and one had limited chronic GVHD. One patient died three months after allogeneic Umbilical Cord Blood (UCB) HSCT from disseminated adenovirus, and the other eight patients are alive without CD therapy or disease symptoms. Curiously, of five allogeneic UCB recipients, none had GVHD, and none had CD3+ and CD33+ donor engraftment after six months. Thus, the door is open to allogeneic UCB HSCT for CD^[53].

CONCLUSION

The challenge is to replicate the most recent Chicago HSCT results and continue to make transplantation safer with a better understanding of the mechanism of HSCT and cell therapy in modifying the natural history of CD.

REFERENCES

- 1 **Baumgart DC**, Sandborn WJ. Crohn's disease. *Lancet* 2012; **380**: 1590-1605 [PMID: [22914295](#) DOI: [10.1016/S0140-6736\(12\)60026-9](#)]
- 2 **Torres J**, Mehandru S, Colombel JF, Peyrin-Biroulet L. Crohn's disease. *Lancet* 2017; **389**: 1741-1755 [PMID: [27914655](#) DOI: [10.1016/S0140-6736\(16\)31711-1](#)]
- 3 **Molodecky NA**, Soon IS, Rabi DM, Ghali WA, Ferris M, Chernoff G, Benchimol EI, Panaccione R, Ghosh S, Barkema HW, Kaplan GG. Increasing incidence and prevalence of the inflammatory bowel diseases with time, based on systematic review. *Gastroenterology* 2012; **142**: 46-54 [PMID: [22001864](#) DOI: [10.1053/j.gastro.2011.10.001](#)]
- 4 **Ng SC**, Shi HY, Hamidi N, Underwood FE, Tang W, Benchimol EI, Panaccione R, Ghosh S, Wu JCY, Chan FKL, Sung JY, Kaplan GG. Worldwide incidence and prevalence of inflammatory bowel disease in the 21st century: a systematic review of population-based studies. *Lancet* 2018; **390**: 2769-2778 [PMID: [29050646](#) DOI: [10.1016/S0140-6736\(17\)32448-0](#)]
- 5 **Lee JC**, Biasci D, Roberts R, Geary RB, Mansfield JC, Ahmad T, Prescott NJ, Satsangi J, Wilson DC, Jostins L, Anderson CA; UK IBD Genetics Consortium, Traherne JA, Lyons PA, Parkes M, Smith KG. Genome-wide association study identifies distinct genetic contributions to prognosis and susceptibility in Crohn's disease. *Nat Genet* 2017; **49**: 262-268 [PMID: [28067912](#) DOI: [10.1038/ng.3755](#)]
- 6 **Verstockt B**, Smith KG, Lee JC. Genome-wide association studies in Crohn's disease: Past, present and future. *Clin Transl Immunology* 2018; **7**: e1001 [PMID: [29484179](#) DOI: [10.1002/cti2.1001](#)]
- 7 **Burgers GJ**, Smeenk G, van der Vegt JH. [An unusual symptom complex as a side effect of glafenine (Glifanin)]. *Ned Tijdschr Geneesk* 1976; **120**: 528-530 [PMID: [2883](#)]
- 8 **Kronman MP**, Zaoutis TE, Haynes K, Feng R, Coffin SE. Antibiotic exposure and IBD development among children: a population-based cohort study. *Pediatrics* 2012; **130**: e794-e803 [PMID: [23008454](#) DOI: [10.1542/peds.2011-3886](#)]
- 9 **Magro F**, Langner C, Driessen A, Ensari A, Geboes K, Mantzaris GJ, Villanacci V, Becheanu G, Borrallho Nunes P, Cathomas G, Fries W, Jouret-Mourin A, Mescoli C, de Petris G, Rubio CA, Shepherd NA, Vieth M, Eliakim R; European Society of Pathology (ESP); European Crohn's and Colitis Organisation (ECCO). European consensus on the histopathology of inflammatory bowel disease. *J Crohns Colitis* 2013; **7**: 827-851 [PMID: [23870728](#) DOI: [10.1016/j.crohns.2013.06.001](#)]
- 10 **Sulz MC**, Burri E, Michetti P, Rogler G, Peyrin-Biroulet L, Seibold F; on behalf of the Swiss IBDnet, an official working group of the Swiss Society of Gastroenterology. Treatment Algorithms for Crohn's Disease. *Digestion* 2020; **101** Suppl 1: 43-57 [PMID: [32172251](#) DOI: [10.1159/000506364](#)]
- 11 **Satsangi J**, Silverberg MS, Vermeire S, Colombel JF. The Montreal classification of inflammatory bowel disease: controversies, consensus, and implications. *Gut* 2006; **55**: 749-753 [PMID: [16698746](#) DOI: [10.1136/gut.2005.082909](#)]
- 12 **Ikehara S**, Good RA, Nakamura T, Sekita K, Inoue S, Oo MM, Muso E, Ogawa K, Hamashima Y. Rationale for bone marrow transplantation in the treatment of autoimmune diseases. *Proc Natl Acad Sci USA* 1985; **82**: 2483-2487 [PMID: [3887403](#) DOI: [10.1073/pnas.82.8.2483](#)]
- 13 **van Bekkum DW**, Bohre EP, Houben PF, Knaan-Shanzer S. Regression of adjuvant-induced arthritis in rats following bone marrow transplantation. *Proc Natl Acad Sci USA* 1989; **86**: 10090-10094 [PMID: [2690067](#) DOI: [10.1073/pnas.86.24.10090](#)]
- 14 **Knaan-Shanzer S**, Houben P, Kinwel-Bohré EP, van Bekkum DW. Remission induction of adjuvant arthritis in rats by total body irradiation and autologous bone marrow transplantation. *Bone Marrow Transplant* 1991; **8**: 333-338 [PMID: [1768966](#)]
- 15 **Ikehara S**. Bone marrow transplantation for autoimmune diseases. *Acta Haematol* 1998; **99**: 116-132 [PMID: [9587393](#) DOI: [10.1159/000040826](#)]
- 16 **Ikehara S**. Stem cell transplantation for autoimmune diseases: what can we learn from experimental models? *Autoimmunity* 2008; **41**: 563-569 [PMID: [18958757](#) DOI: [10.1080/08916930802197909](#)]
- 17 **van Bekkum DW**. Autologous stem cell transplantation for treatment of autoimmune diseases. *Stem Cells*

- 1999; **17**: 172-178 [PMID: [10342560](#) DOI: [10.1002/stem.170172](#)]
- 18 **Cominelli F**, Arseneau KO, Rodriguez-Palacios A, Pizarro TT. Uncovering Pathogenic Mechanisms of Inflammatory Bowel Disease Using Mouse Models of Crohn's Disease-Like Ileitis: What is the Right Model? *Cell Mol Gastroenterol Hepatol* 2017; **4**: 19-32 [PMID: [28560286](#) DOI: [10.1016/j.jemgh.2017.02.010](#)]
- 19 **Godoi DF**, Cardoso CR, Ferraz DB, Provinciatio PR, Cunha FQ, Silva JS, Voltarelli JC. Hematopoietic SCT modulates gut inflammation in experimental inflammatory bowel disease. *Bone Marrow Transplant* 2010; **45**: 1562-1571 [PMID: [20228850](#) DOI: [10.1038/bmt.2010.6](#)]
- 20 **Burt RK**, Traynor A, Oyama Y, Craig R. High-dose immune suppression and autologous hematopoietic stem cell transplantation in refractory Crohn disease. *Blood* 2003; **101**: 2064-2066 [PMID: [12393477](#) DOI: [10.1182/blood-2002-07-2122](#)]
- 21 **Corraliza AM**, Ricart E, López-García A, Carne Masamunt M, Veny M, Esteller M, Mayorgas A, Le Bourhis L, Allez M, Planell N, Visvanathan S, Baum P, España C, Cabezón-Cabello R, Benítez-Ribas D, Rovira M, Panés J, Salas A. Differences in Peripheral and Tissue Immune Cell Populations Following Haematopoietic Stem Cell Transplantation in Crohn's Disease Patients. *J Crohns Colitis* 2019; **13**: 634-647 [PMID: [30521002](#) DOI: [10.1093/ecco-jcc/jjy203](#)]
- 22 **Drakos PE**, Nagler A, Or R. Case of Crohn's disease in bone marrow transplantation. *Am J Hematol* 1993; **43**: 157-158 [PMID: [8342550](#) DOI: [10.1002/ajh.2830430223](#)]
- 23 **Lopez-Cubero SO**, Sullivan KM, McDonald GB. Course of Crohn's disease after allogeneic marrow transplantation. *Gastroenterology* 1998; **114**: 433-440 [PMID: [9496932](#) DOI: [10.1016/s0016-5085\(98\)70525-6](#)]
- 24 **Kashyap A**, Forman SJ. Autologous bone marrow transplantation for non-Hodgkin's lymphoma resulting in long-term remission of coincidental Crohn's disease. *Br J Haematol* 1998; **103**: 651-652 [PMID: [9858212](#) DOI: [10.1046/j.1365-2141.1998.01059.x](#)]
- 25 **Musso M**, Porretto F, Crescimanno A, Bondi F, Polizzi V, Scalone R. Crohn's disease complicated by relapsed extranodal Hodgkin's lymphoma: prolonged complete remission after unmanipulated PBPC autotransplant. *Bone Marrow Transplant* 2000; **26**: 921-923 [PMID: [11081397](#) DOI: [10.1038/sj.bmt.1702621](#)]
- 26 **Ditschkowski M**, Einsele H, Schwerdtfeger R, Bunjes D, Trenchel R, Beelen DW, Elmaagacli AH. Improvement of inflammatory bowel disease after allogeneic stem-cell transplantation. *Transplantation* 2003; **75**: 1745-1747 [PMID: [12777867](#) DOI: [10.1097/01.TP.0000062540.29757.E9](#)]
- 27 **Söderholm JD**, Malm C, Juliusson G, Sjö Dahl R. Long-term endoscopic remission of crohn disease after autologous stem cell transplantation for acute myeloid leukaemia. *Scand J Gastroenterol* 2002; **37**: 613-616 [PMID: [12059066](#) DOI: [10.1080/00365520252903198](#)]
- 28 **Kreisel W**, Potthoff K, Bertz H, Schmitt-Graeff A, Ruf G, Rasenack J, Finke J. Complete remission of Crohn's disease after high-dose cyclophosphamide and autologous stem cell transplantation. *Bone Marrow Transplant* 2003; **32**: 337-340 [PMID: [12858208](#) DOI: [10.1038/sj.bmt.1704134](#)]
- 29 **Oyama Y**, Craig RM, Traynor AE, Quigley K, Statkute L, Halverson A, Brush M, Verda L, Kowalska B, Krosnjak N, Kletzel M, Whittington PF, Burt RK. Autologous hematopoietic stem cell transplantation in patients with refractory Crohn's disease. *Gastroenterology* 2005; **128**: 552-563 [PMID: [15765390](#) DOI: [10.1053/j.gastro.2004.11.051](#)]
- 30 **Cassinotti A**, Annaloro C, Ardizzone S, Onida F, Della Volpe A, Clerici M, Usardi P, Greco S, Maconi G, Porro GB, Deliliers GL. Autologous haematopoietic stem cell transplantation without CD34+ cell selection in refractory Crohn's disease. *Gut* 2008; **57**: 211-217 [PMID: [17895357](#) DOI: [10.1136/gut.2007.128694](#)]
- 31 **Clerici M**, Cassinotti A, Onida F, Trabattini D, Annaloro C, Della Volpe A, Rainone V, Lissini F, Duca P, Sampietro G, Fociani P, Vago G, Foschi D, Ardizzone S, Deliliers GL, Porro GB. Immunomodulatory effects of unselected haematopoietic stem cells autotransplantation in refractory Crohn's disease. *Dig Liver Dis* 2011; **43**: 946-952 [PMID: [21907652](#) DOI: [10.1016/j.dld.2011.07.021](#)]
- 32 **Hommes DW**, Duijvestein M, Zelinkova Z, Stokkers PC, Ley MH, Stoker J, Voermans C, van Oers MH, Kersten MJ. Long-term follow-up of autologous hematopoietic stem cell transplantation for severe refractory Crohn's disease. *J Crohns Colitis* 2011; **5**: 543-549 [PMID: [22115372](#) DOI: [10.1016/j.crohns.2011.05.004](#)]
- 33 **Hawkey CJ**, Allez M, Clark MM, Labopin M, Lindsay JO, Ricart E, Rogler G, Rovira M, Satsangi J, Danese S, Russell N, Gribben J, Johnson P, Larghero J, Thieblemont C, Ardizzone S, Dierickx D, Ibatici A, Littlewood T, Onida F, Schanz U, Vermeire S, Colombel JF, Jouet JP, Clark E, Saccardi R, Tyndall A, Travis S, Farge D. Autologous Hematopoietic Stem Cell Transplantation for Refractory Crohn Disease: A Randomized Clinical Trial. *JAMA* 2015; **314**: 2524-2534 [PMID: [26670970](#) DOI: [10.1001/jama.2015.16700](#)]
- 34 **Burt RK**, Ruiz MA, Kaiser RL Jr. Stem Cell Transplantation for Refractory Crohn Disease. *JAMA* 2016; **315**: 2620 [PMID: [27327808](#) DOI: [10.1001/jama.2016.4030](#)]
- 35 **Lindsay JO**, Allez M, Clark M, Labopin M, Ricart E, Rogler G, Rovira M, Satsangi J, Farge D, Hawkey CJ; ASTIC trial group; European Society for Blood and Marrow Transplantation Autoimmune Disease Working Party; European Crohn's and Colitis Organisation. Autologous stem-cell transplantation in treatment-refractory Crohn's disease: an analysis of pooled data from the ASTIC trial. *Lancet Gastroenterol Hepatol* 2017; **2**: 399-406 [PMID: [28497755](#) DOI: [10.1016/S2468-1253\(17\)30056-0](#)]
- 36 **López-García A**, Rovira M, Jauregui-Amezaga A, Marín P, Barastegui R, Salas A, Ribas V, Feu F, Elizalde JI, Fernández-Avilés F, Martínez C, Gutiérrez G, Rosiñol L, Carreras E, Urbano A, Lozano M, Cid J, Suárez-Lledó M, Masamunt MC, Comas D, Giner A, Gallego M, Alfaro I, Ordás I, Panés J, Ricart E. Autologous Haematopoietic Stem Cell Transplantation for Refractory Crohn's Disease: Efficacy in a Single-Centre Cohort. *J Crohns Colitis* 2017; **11**: 1161-1168 [PMID: [28419282](#) DOI: [10.1093/ecco-jcc/jjx054](#)]
- 37 **Ruiz MA**, Kaiser Junior RL, Gouvêa Faria MA, de Quadros LG. Remission of refractory Crohn's disease after autologous hematopoietic stem cell transplantation. *Rev Bras Hematol Hemoter* 2015; **37**: 136-139 [PMID: [25818827](#) DOI: [10.1016/j.bjhh.2015.01.002](#)]
- 38 **Siqueira RC**, Kaiser Junior RL, Ruiz LP, Ruiz MA. Ischemic retinopathy associated with Crohn's disease. *Int Med Case Rep J* 2016; **9**: 197-200 [PMID: [27524921](#) DOI: [10.2147/IMCRJ.S108855](#)]
- 39 **Ruiz MA**, Kaiser Junior RL, de Quadros LG, Caseiro GHX, Oliveira AF, Peña-Arciniegas T, Piron-Ruiz L,

- Kaiser FSL, Oliveira VL. Hematopoietic stem cell transplantation in a severe refractory Crohn's disease patient with intestinal stoma: a case report. *Int Med Case Rep J* 2017; **10**: 353-359 [PMID: 29123428 DOI: 10.2147/IMCRJ.S139552]
- 40 **Ruiz MA**, Kaiser Junior RL, Piron-Ruiz L, Peña-Arciniegas T, Saran PS, De Quadros LG. Hematopoietic stem cell transplantation for Crohn's disease: Gaps, doubts and perspectives. *World J Stem Cells* 2018; **10**: 134-137 [PMID: 30397423 DOI: 10.4252/wjsc.v10.i10.134]
- 41 **Rodrigues MC**, Hamerschlak N, de Moraes DA, Simões BP, Rodrigues M, Ribeiro AA, Voltarelli JC. Guidelines of the Brazilian society of bone Marrow transplantation on hematopoietic stem cell transplantation as a treatment for the autoimmune diseases systemic sclerosis and multiple sclerosis. *Rev Bras Hematol Hemoter* 2013; **35**: 134-143 [PMID: 23741192 DOI: 10.5581/1516-8484.20130035]
- 42 **Oliveira MC**, Elias JB, Moraes DA, Simões BP, Rodrigues M, Ribeiro AAF, Piron-Ruiz L, Ruiz MA, Hamerschlak N. A review of hematopoietic stem cell transplantation for autoimmune diseases: multiple sclerosis, systemic sclerosis and Crohn's disease. Position paper of the Brazilian Society of Bone Marrow Transplantation. *Hematol Transfus Cell Ther* 2020; S2531-1379 [PMID: 32418777 DOI: 10.1016/j.htct.2020.03.002]
- 43 **Ruiz MA**, Kaiser RL Jr, de Quadros LG, Piron-Ruiz L, Peña-Arciniegas T, Faria MAG, Siqueira RC, Pirozzi FF, Kaiser FSL, Burt RK. Low toxicity and favorable clinical and quality of life impact after non-myeloablative autologous hematopoietic stem cell transplant in Crohn's disease. *BMC Res Notes* 2017; **10**: 495 [PMID: 28985769 DOI: 10.1186/s13104-017-2824-1]
- 44 **Duarte RF**, Labopin M, Bader P, Basak GW, Bonini C, Chabannon C, Corbacioglu S, Dreger P, Dufour C, Gennery AR, Kuball J, Lankester AC, Lanza F, Montoto S, Nagler A, Peffault de Latour R, Snowden JA, Styczynski J, Yakoub-Agha I, Kröger N, Mohty M; European Society for Blood and Marrow Transplantation (EBMT). Indications for haematopoietic stem cell transplantation for haematological diseases, solid tumours and immune disorders: current practice in Europe, 2019. *Bone Marrow Transplant* 2019; **54**: 1525-1552 [PMID: 30953028 DOI: 10.1038/s41409-019-0516-2]
- 45 **D'Souza A**, Lee S, Zhu X, Pasquini M. Current Use and Trends in Hematopoietic Cell Transplantation in the United States. *Biol Blood Marrow Transplant* 2017; **23**: 1417-1421 [PMID: 28606646 DOI: 10.1016/j.bbmt.2017.05.035]
- 46 **Kelsey PJ**, Oliveira MC, Badoglio M, Sharrack B, Farge D, Snowden JA. Haematopoietic stem cell transplantation in autoimmune diseases: From basic science to clinical practice. *Curr Res Transl Med* 2016; **64**: 71-82 [PMID: 27316390 DOI: 10.1016/j.retram.2016.03.003]
- 47 **Jessop H**, Farge D, Saccardi R, Alexander T, Rovira M, Sharrack B, Greco R, Wulfraat N, Moore J, Kazmi M, Badoglio M, Adams G, Verhoeven B, Murray J, Snowden JA. General information for patients and carers considering haematopoietic stem cell transplantation (HSCT) for severe autoimmune diseases (ADs): A position statement from the EBMT Autoimmune Diseases Working Party (ADWP), the EBMT Nurses Group, the EBMT Patient, Family and Donor Committee and the Joint Accreditation Committee of ISCT and EBMT (JACIE). *Bone Marrow Transplant* 2019; **54**: 933-942 [PMID: 30705338 DOI: 10.1038/s41409-019-0430-7]
- 48 **Snowden JA**, Sharrack B, Akil M, Kiely DG, Lobo A, Kazmi M, Muraro PA, Lindsay JO. Autologous haematopoietic stem cell transplantation (aHSCT) for severe resistant autoimmune and inflammatory diseases - a guide for the generalist. *Clin Med (Lond)* 2018; **18**: 329-334 [PMID: 30072560 DOI: 10.7861/clinmedicine.18-4-329]
- 49 **Conselho Federal de Medicina**. Código de Ética Médica: Resolução CFM nº2.217, de setembro de 2018/C - Brasília; Conselho Federal de Medicina, 2019. 108p. ISBN: 978-85-87077-68-4. (Portuguese)
- 50 Conselho Federal de Medicina - Posição do CFM sobre o tratamento da Doença de Crohn com o TCTH - PROCESSO-CONSULTA nº 5/2019 – PARECER CFM nº 6/2019 INTERESSADO: 3ª Vara Cível da Comarca de Americana (SP), Tribunal de Justiça de São Paulo. ASSUNTO: Transplante de medula óssea para doença de Crohn. (Portuguese)
- 51 Tribunal de Justiça do Distrito Federal e dos Territórios (Acórdão 1151441, 07041199520178070001, Relator: SILVA LEMOS, 5ª Turma Cível, data de julgamento: 13/02/2019, Publicado no DJe: 15/03/2019) (Portuguese) Available from: <https://www.tjdft.jus.br/consultas/jurisprudencia/jurisprudencia-em-temas/jurisprudencia-em-detalhes/plano-de-saude/tratamento-experimental>
- 52 **Burt RK**, Craig R, Yun L, Halverson A, Quigley K, Arnautovic I, Han X. A pilot feasibility study of non-myeloablative allogeneic hematopoietic stem cell transplantation for refractory Crohn Disease. *Bone Marrow Transplant* 2020 [PMID: 32467584 DOI: 10.1038/s41409-020-0953-y]
- 53 **Ruiz MA**, Junior RLK, Quadros LG. Is it time to use hematopoietic stem cell transplantation for severe and refractory crohn's disease? *Hematol Transfus Cell Ther* 2020; **42**: 190-191 [PMID: 31601485 DOI: 10.1016/j.htct.2019.06.002]



Published by **Baishideng Publishing Group Inc**
7041 Koll Center Parkway, Suite 160, Pleasanton, CA 94566, USA

Telephone: +1-925-3991568

E-mail: bpgoffice@wjgnet.com

Help Desk: <https://www.f6publishing.com/helpdesk>

<https://www.wjgnet.com>

